



## MS AKT Practice Paper 4

A suite of practice papers is available to help medical students prepare for the UK Medical School Applied Knowledge Test (MS AKT). Please note that while this practice paper reflects the style and type of questions that students will encounter in the MS AKT, it is not blueprinted to the MLA Content Map.

This practice paper comes with and without the answer options.

We would like to recognise the contribution of medical schools, and members of the AKT working groups in particular, for their help in preparing these which we hope students will find a valuable resource.

Please note the practice papers are reviewed on an annual basis and updated accordingly. Items that may have appeared in earlier versions may now have been retired as part of this exercise. Should you have any questions about the clinical content of the practice exam please speak to the Assessment Lead in your school in the first instance.

**Any redistribution or reproduction of part or all of the contents in any form is prohibited other than for personal, educational and non-commercial use.**



1. A 48 year old man has 1 day of severe right upper quadrant pain. He has vomited five times. He smokes 10 cigarettes per day and drinks 31 units of alcohol per week.

His temperature is 37.8°C, pulse 90 bpm and BP 140/84 mmHg. He is tender in the epigastrium and right upper quadrant, and there is voluntary guarding.

Investigations:

White cell count	15 × 10 <sup>9</sup> /L	(3.8–10.0)
ALT	41 IU/L	(10–50)
Alkaline phosphatase	125 IU/L	(25–115)
Bilirubin	14 µmol/L	(<17)
Amylase	222U/L	(<220)
CRP	42 mg/L	(<5)

What is the most likely diagnosis?

- A. Acute cholangitis
- B. Acute cholecystitis
- C. Acute hepatitis
- D. Acute pancreatitis
- E. Biliary colic

2. A 65 year old woman has had disorientation and dizziness for one week. She has headaches that are worse when bending over and associated with vomiting. She had a non-small cell lung cancer that was treated with radical radiotherapy two years ago.

BP is 178/95 mmHg. She has no focal neurological signs.

What is the most likely diagnosis?

- A. Cerebral metastases
- B. Hypercalcaemia
- C. Hyponatraemia
- D. Paraneoplastic encephalitis
- E. Severe hypertension



- 3.** An 66 year old woman with advanced bowel cancer is taking morphine sulfate modified release, 30 mg twice daily for abdominal pain. She is in the last days of life and is now unable to swallow oral medications. She has not needed any doses for breakthrough pain.

Investigations:

eGFR 51 mL/min/1.73 m<sup>2</sup> (>60)

A continuous subcutaneous infusion of morphine sulfate is required, as a direct conversion from oral morphine sulfate.

Which is the correct dose of morphine sulfate to prescribe over 24 hours?

- A.** 15 mg
- B.** 30 mg
- C.** 60 mg
- D.** 90 mg
- E.** 120 mg

- 4.** A 24 year old man develops low back pain the day after falling while playing tennis. He is usually well and takes no regular medication. He is a laboratory technician.

What is the most appropriate advice?

- A.** Avoid work until the pain has completely settled
- B.** Back strengthening exercises
- C.** Bed rest until pain improves, then gradual mobilisation
- D.** Continue usual activity
- E.** Self referral for physiotherapy



- 5.** A 44 year old woman has shooting pain in her left leg. She has an advanced rectal cancer compressing the sciatic nerve. She is taking morphine sulfate modified release 20 mg twice daily. This is providing some benefit but not fully controlling her pain.

Which is the most appropriate additional medication?

- A.** Oral amitriptyline
- B.** Oral diclofenac
- C.** Oral tramadol
- D.** Oral venlafaxine
- E.** Topical ibuprofen

- 6.** A 67 year old man attends the emergency department feeling generally unwell with no specific symptoms. He is being treated with neoadjuvant chemotherapy for bowel cancer. He underwent the third cycle 8 days ago.

His temperature is 38.6°C, pulse 97 bpm, BP 132/68 mmHg, respiratory rate 12 breaths per minute and oxygen saturation 95% breathing air. Examination is otherwise unremarkable.

Blood tests have been taken, but results are not yet available.

What is the most appropriate next step in management?

- A.** Admit to medical receiving unit
- B.** Await blood results before taking further action
- C.** Discuss with local oncology team for advice
- D.** Give intravenous broad-spectrum antibiotics
- E.** Give intravenous fluid therapy



- 7.** A 67 year old woman has right-sided pleuritic chest pain and breathlessness of sudden onset. She had a bleeding peptic ulcer secondary to NSAID use 4 weeks ago requiring a 2-unit blood transfusion. She has osteoarthritis. She takes lansoprazole and co-codamol.

Her pulse is 112 bpm, BP 114/74 mmHg, respiratory rate 26 breaths per minute and oxygen saturation 94% breathing 40% oxygen. Her chest is clear.

Investigations:

Haemoglobin	93 g/L	(115–150)
Creatinine	81 $\mu$ mol/L	(60–120)

CT pulmonary angiogram: thrombus in both pulmonary arteries

What is the most appropriate initial treatment?

- A.** Insertion of vena cava filter
- B.** Intravenous alteplase
- C.** Intravenous heparin
- D.** Oral apixaban
- E.** Subcutaneous dalteparin sodium



- 8.** A 88 year old woman has 30 hours of severe abdominal pain. She was discharged from hospital 4 weeks ago following an aortobifemoral bypass graft.

She has diffuse tenderness of the abdomen with absent bowel sounds. Plain X-ray of the abdomen is unremarkable.

Investigations:

Haemoglobin	114 g/L	(115-160)
White cell count	$18 \times 10^9/L$	(3.8–10.0)
Urea	16.4 mmol/L	(2.5–7.8)
Creatinine	158 $\mu\text{mol/L}$	(60–120)
CRP	110 mg/L	(<5)

Arterial blood gas breathing air

pH	7.28	(7.35–7.45)
PO <sub>2</sub>	13 kPa	(11–15)
PCO <sub>2</sub>	4.6 kPa	(4.6–6.4)
Bicarbonate	16 mmol/L	(22–30)

Lactate	4.5 mmol/L	(1–2)
---------	------------	-------

What is the most likely diagnosis?

- A.** Acute diverticulitis
- B.** Acute pancreatitis
- C.** Incarcerated paraumbilical hernia
- D.** Mesenteric ischaemia
- E.** Ruptured aortic aneurysm



9. A 59 year old woman has 4 days of sharp central chest pain that radiates into her back and is worse on lying flat.

Her temperature is 37.7°C, pulse 105 bpm, BP 100/72 mmHg, respiratory rate 18 breaths per minute and oxygen saturation 96% breathing air. Heart sounds are normal, brachial pulses in both arms are synchronous.

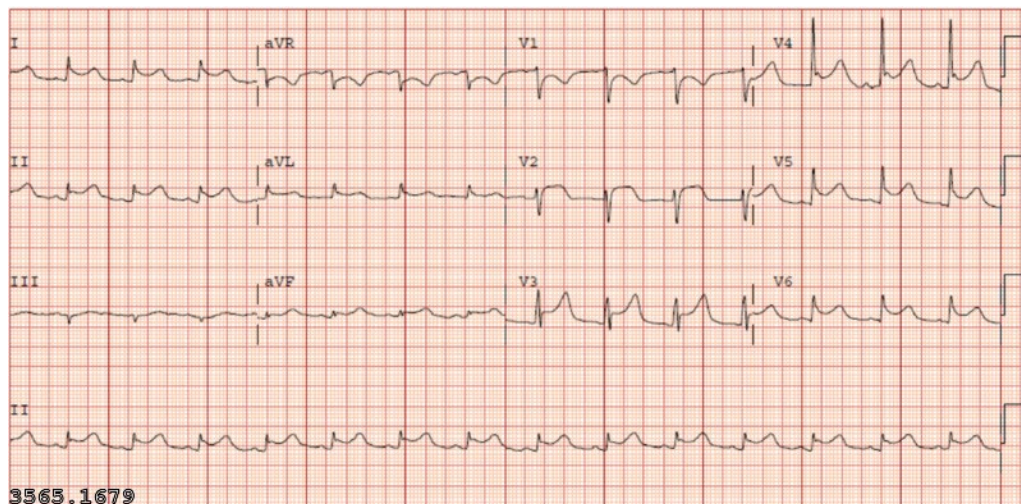
Investigations:

Haemoglobin	152 g/L	(115–160)
White cell count	$11 \times 10^9/\text{L}$	(3.8–10.0)
Platelets	$390 \times 10^9/\text{L}$	(150–400)
Neutrophils	$7.5 \times 10^9/\text{L}$	(2.0–7.5)
D dimers	0.5 mg/L	(<0.5)

Troponin T 0.5 µg/L (<0.01)

CRP 30 mg/L (<5)

ECG: see image



What is the most likely diagnosis?

- A. Acute coronary syndrome
- B. Aortic dissection
- C. Musculoskeletal chest pain
- D. Pericarditis
- E. Pneumonia



- 10.** The surgical registrar is running late due to a fault with their car. She asks the surgical Foundation Year 1 doctor (FY1) to obtain written consent from the patients on the afternoon list to avoid a delayed start and possible cancellations. The list is three Dupuytren's contracture releases. The FY1 has not assisted with this operation on this rotation.

What is the most appropriate action for the FY1 to take?

- A.** Ask the consultant to consent the patients
- B.** Consent all of the patients
- C.** Consent all of the patients and ask the registrar to countersign the forms
- D.** Only consent the patients without significant medical conditions
- E.** Refuse to consent the patients

- 11.** A 33 year old man has 12 hours of severe, constant pain of sudden onset radiating from the right flank to the groin. He has no significant past medical history.

Urinalysis shows blood 2+, protein negative and leucocytes 1+.

Which is the most appropriate initial investigation?

- A.** Contrast CT of abdomen and pelvis
- B.** Intravenous urography
- C.** Non-contrast CT of renal tract
- D.** Plain X-ray of renal tract
- E.** Ultrasonography of renal tract





- 12.** A 63 year old man attends his GP for review following addition of chlortalidone to maximal-dose ramipril for BP control. He also has type 2 diabetes mellitus and chronic kidney disease, and takes metformin. His creatinine 1 month ago was 115  $\mu\text{mol/L}$  (60–120).

His BP is 133/85 mmHg.

Investigations:

Sodium	135 mmol/L	(135–146)
Potassium	4.6 mmol/L	(3.5–5.3)
Urea	9.0 mmol/L	(2.5–7.8)
Creatinine	140 $\mu\text{mol/L}$	(60–120)
eGFR	44 mL/min/1.73 m <sup>2</sup>	(>60)

Which is the most appropriate management?

- A.** Stop metformin
- B.** Repeat urea and electrolytes in 2 weeks
- C.** Stop chlortalidone
- D.** Stop ramipril
- E.** Switch chlortalidone to amlodipine

- 13.** A 40 year old woman has 1 day of a painful, swollen left elbow and fever. She has rheumatoid arthritis and takes methotrexate and infliximab.

Her temperature is 38.2°C, pulse 100 bpm and BP 119/83 mmHg. The left elbow is swollen and erythematous.

Investigations:

White cell count	16.4 $\times 10^9/\text{L}$	(3.8–10.0)
Urea	6.7 mmol/L	(2.5–7.8)
Creatinine	98 $\mu\text{mol/L}$	(60–120)
CRP	171 mg/L	(<5)

Joint aspiration: no organisms on Gram stain, white cell count 2043/ $\mu\text{L}$  (<200), mostly neutrophils, no crystals.

She is advised to take oral paracetamol.

What is the most appropriate additional management?

- A.** Inject methylprednisolone into the joint
- B.** Intravenous flucloxacillin
- C.** No further treatment pending culture results
- D.** Oral colchicine
- E.** Oral prednisolone



- 14.** A 33 year old man is found collapsed on the medical ward. He was admitted 3 days ago with urosepsis and is being treated with intravenous antibiotics. He has type 1 diabetes and has been taking his usual doses of subcutaneous insulin.

He is unrousable and is clammy. His capillary blood glucose is 2.1 mmol/L.

What is the most appropriate immediate treatment?

- A.** 20 mL of 50% glucose by slow intravenous injection
- B.** 75 mL of 20% glucose by intravenous infusion
- C.** 150 mL of 5% glucose by intravenous infusion
- D.** Glucagon 1 mg by intramuscular injection
- E.** Glucose gel 25 g (contains 10 g glucose) applied to buccal mucosa

- 15.** A 67 year old woman with type 2 diabetes mellitus attends the clinic for review. Her metformin treatment was stopped during a recent hospital admission with a hip fracture, in view of worsening chronic kidney disease (eGFR 28 mL/min/1.73 m<sup>2</sup> (>60)). She has diverticular disease. She takes the maximum dose of gliclazide.

Investigations: Glycated haemoglobin 79 mmol/mol (20–42) She is keen to avoid giving herself injections.

What is the most appropriate additional treatment?

- A.** Acarbose ( $\alpha$ -glucosidase inhibitor)
- B.** Dulaglutide (GLP-1 agonist)
- C.** Empagliflozin (SGLT2 inhibitor)
- D.** Pioglitazone (thiazolidinedione)
- E.** Sitagliptin (DPP4 inhibitor)



**16.** A 62 year old Indian woman attends her GP for an NHS health check.

Her BMI is 34 kg/m<sup>2</sup>. Her BP is 110/84 mmHg. Urinalysis is normal.

Investigations:

Glycated haemoglobin 45 mmol/mol (20–42)

What is the most appropriate next step in management?

- A.** Advise a low sugar diet
- B.** Prescribe metformin
- C.** Prescribe ramipril
- D.** Refer her to the Diabetes Prevention Programme
- E.** Send off a fasting plasma glucose

**17.** A 53 year old woman has 6 days of worsening abdominal pain. She has also had recent constipation. There is no rectal bleeding.

Her temperature is 37.8°C, pulse 105 bpm and BP 140/85 mmHg. She has tenderness in the left iliac fossa with some guarding. Bowel sounds are normal. Rectal examination shows hard stools only.

What is the most likely diagnosis?

- A.** Ischaemic colitis
- B.** Meckel diverticulitis
- C.** Proctocolitis
- D.** Rectal carcinoma
- E.** Sigmoid diverticulitis



- 18.** A 76 year old man has nausea, fever and rigors. He also has foul smelling urine. He was discharged 3 days ago after being treated for a PE. He has been having low molecular weight heparin injections twice daily since the diagnosis. He had a cholecystectomy 12 years ago.

His temperature is 39.7°C, pulse 100 bpm and BP 92/41 mmHg.

Investigations:

APTT 43 seconds (22–41)

PT 18 seconds (10–12)

What is the most likely cause of the prolonged prothrombin time?


- A.** Disseminated intravascular coagulation
- B.** Liver disease
- C.** Low molecular weight heparin
- D.** Lupus anticoagulant
- E.** Vitamin K deficiency

- 19.** A 62 year old man has a right-sided hearing loss. There has been slow deterioration over the previous two years, and he is now also troubled by non-pulsatile, right-sided tinnitus that prevents him from sleeping.

A pure-tone audiogram shows a right-sided high-frequency hearing loss. He has normal tympanometry bilaterally.

Which is the most appropriate diagnostic investigation?

- A.** Cerebral angiography
- B.** CT of head
- C.** CT of petrous temporal bones
- D.** MR imaging of internal acoustic meatus
- E.** PET–CT of brain



- 20.** A 65 year old woman has had bloody diarrhoea six times each day for the past 4 weeks and is feeling unwell. She has noticed urgency to pass stool and has to get up in the night to pass stool. Her left eye has been red, but not painful.

Her temperature is 38.5°C, pulse 109 bpm, BP 110/70 mmHg and respiratory rate 22 breaths per minute.

Investigations: Stool culture: negative

What is the most likely diagnosis?

- A.** Adenocarcinoma of the colon
- B.** Crohn disease
- C.** Irritable bowel syndrome
- D.** Microscopic colitis
- E.** Ulcerative colitis

- 21.** A 28 year old man attends his GP with 7 weeks of right iliac fossa pain, weight loss of 3 kg and diarrhoea five times a day. He previously opened his bowels once daily. He has not travelled abroad. He lives with his partner, who is well.

Rectal examination is normal.

Investigations:

Haemoglobin	129 g/L	(135-180 g/l)
White cell count	$11.4 \times 10^9/L$	(3.8–10.0)
Platelets	$450 \times 10^9/L$	(150–400)
Erythrocyte sedimentation rate	60 mm/hr	(<20)
ALT	10 IU/L	(10–50)
ALP	110 IU/L	(25–115)
Bilirubin	15 $\mu\text{mol/L}$	(<17)
Albumin	32 g/L	(35–50)

Which is the most appropriate next investigation?

- A.** Antimitochondrial antibodies
- B.** Anti-tissue transglutaminase antibodies
- C.** Faecal calprotectin
- D.** Faecal occult blood testing
- E.** Stool cultures



**22.** A 49 year old woman is undergoing investigation for headaches. She has no visual symptoms.

Her visual acuity is 6/5 bilaterally. There is a visual field defect.

Investigations:

MR scan of brain: pituitary adenoma indenting the optic chiasm

Which is the most likely visual field defect?

- A. Bilateral concentric visual loss
- B. Bilaterally enlarged blind spots
- C. Bitemporal hemianopia
- D. Left-sided homonymous hemianopia
- E. Right-sided homonymous hemianopia

**23.** A 36 year old man has recurrent episodes of collapse over 4 months. When laughing, his muscles feel limp and he falls to the floor, but remains conscious. He has anxiety and depression and takes citalopram. His father died from an ischaemic stroke aged 59 years.

Which is the most likely diagnosis?

- A. Cardiogenic syncope
- B. Cataplexy
- C. Cough syncope
- D. Dissociative (non-epileptic) seizures
- E. Epilepsy



- 24.** A 37 year old man has 4 weeks of pain on the radial side of his left wrist. The pain is worse when he plays the piano. He has no history of trauma.

He has swelling and tenderness over the distal end of the left radial styloid. The pain is exacerbated by ulnar deviation of the wrist when the thumb is clasped in the palm.

What is the most likely diagnosis?

- A.** De Quervain tendinopathy
- B.** Ganglion cyst
- C.** Intersection syndrome
- D.** Osteoarthritis of the trapeziometacarpal joint
- E.** Scaphoid fracture

- 25.** A 41 year old woman is admitted following a significant overdose of amitriptyline and propranolol taken 30 minutes ago.

Her GCS is 15. Her pulse is 80 bpm, BP 134/90 mmHg, respiratory rate 14 breaths per minute and oxygen saturation 98% breathing air.

Investigations:

Arterial blood gas breathing air	pH 7.42	(7.35–7.45)
PO <sub>2</sub>	11.7 kPa	(11–15)
PCO <sub>2</sub>	4.9 kPa	(4.6–6.4)
Bicarbonate	24 mmol/L	(22–30)

ECG: sinus rhythm, QRS duration 100 ms (80–120)

What is the most appropriate next step in management?

- A.** Arrange gastric lavage
- B.** Give oral activated charcoal
- C.** Give oral ipecacuanha
- D.** Start IV 1.26% sodium bicarbonate
- E.** Start IV acetylcysteine



**26.** A 48 year old man has 8 months of a painful, stiff left shoulder. The pain is dull and worse at night. There is no history of trauma.

He has type 1 diabetes mellitus. He has reduced passive and active range of movement in the left shoulder with pain at extremes of range of motion. Neck movements are normal. Power and sensation are normal.

Investigations:

CRP 6mg/L (<5)

What is the most likely diagnosis?

- A.** Adhesive capsulitis
- B.** Glenohumeral osteoarthritis
- C.** Polymyalgia rheumatica
- D.** Rotator cuff tear
- E.** Subacromial bursitis

**27.** A 57 year old woman is reviewed following a bone densitometry scan (DXA). She was recently found to have polymyalgia rheumatica, and treatment with oral prednisolone was started.

The T-score for the bone mineral density in her femoral neck is  $-3.9$ .

She is advised to take colecalciferol with calcium carbonate.

What is the most appropriate additional treatment?

- A.** Alendronic acid
- B.** Denosumab
- C.** No additional treatment
- D.** Raloxifene hydrochloride
- E.** Teriparatide





**28.** A 66 year old woman attends the GP with 7 weeks of intermittent dizziness that she describes as 'the room spinning'. The episodes start suddenly, are usually triggered by looking upwards, and last less than a minute before resolving completely. She reports nausea during these episodes. She is otherwise well.

Otoscopic and neurological examinations are normal.

What is the most likely diagnosis?

- A.** Acoustic neuroma
- B.** Benign paroxysmal positional vertigo
- C.** Cerebellar lesion
- D.** Ménière disease
- E.** Vestibular neuritis

**29.** A 62 year old man becomes increasingly breathless 3 hours after the removal of a chest drain. The chest drain was inserted for a right-sided pleural effusion secondary to lymphoma . Three litres of bloodstained fluid were drained before removal.

What is the most likely diagnosis?

- A.** Aspiration pneumonia
- B.** Pneumothorax
- C.** Pulmonary embolism
- D.** Pulmonary oedema
- E.** Recurrence of effusion



- 30.** A 38 year old woman has abdominal pain 7 days after a laparoscopic sleeve gastrectomy for weight loss.

Her temperature is 36.5°C, pulse 110 bpm, BP 120/72 mmHg and oxygen saturation 96% breathing oxygen 4 L/min via nasal prongs. She has reduced breath sounds in both bases. She has abdominal tenderness with guarding and reduced bowel sounds.

What is the most appropriate diagnostic investigation?

- A.** Abdominal X-ray
- B.** Barium enema
- C.** CT of abdomen
- D.** Erect chest X-ray
- E.** Point-of-care FAST scan

- 31.** A 25 year old woman is short of breath 12 hours after abdominal surgery for adhesions.

Her pulse is 119 bpm, BP 92/54 mmHg, respiratory rate 24 breaths per minute and oxygen saturation 96% breathing oxygen 4 L/minute via nasal cannulae. She has a large volume of blood in her abdominal drains.

She is treated with an IV fluid bolus, and the surgical registrar is informed.

What is the most appropriate next management step?

- A.** Activate major haemorrhage protocol
- B.** Give IV noradrenaline/norepinephrine
- C.** Give IV tranexamic acid
- D.** Give prothrombin complex concentrate
- E.** Increase oxygen to 15 L/min via a non-rebreather mask



- 32.** A 59 year old man attends the GP for review. He has type 1 diabetes mellitus, hypertension, ischaemic heart disease and CKD stage 4 (recent eGFR 25 mL/min/1.73 m<sup>2</sup> (> 60)). He takes insulin, lisinopril, metoprolol tartrate and aspirin.

His BP is 160/96 mmHg. He has pitting oedema to the mid shin. Urinalysis shows protein 2+.

Investigations:

Sodium	144 mmol/L	(135–146)
Potassium	5.4 mmol/L	(3.5–5.3)
Urea	19.2 mmol/L	(2.5–7.8)
Creatinine	237 µmol/L	(60–120)
eGFR	26 mL/min/1.73 m <sup>2</sup>	(>60)

What is the most appropriate therapeutic change?

- A. Add indapamide
- B. Add furosemide
- C. Add spironolactone
- D. Stop lisinopril
- E. Switch lisinopril to losartan

- 33.** A 30 year old woman is brought to the resuscitation room of the emergency department after being kicked by a horse . She is 28 weeks pregnant. Her cervical spine is immobilised.

She is conscious and asks about her baby.

Her temperature is 37°C, pulse 100 bpm, BP 78/56 mmHg and oxygen saturation 99% breathing 40% oxygen.

Fluid resuscitation has been started and bloods have been sent.

What is the most appropriate next step?

- A. Image the long bones and pelvis, and orthopaedic review
- B. Perform a full primary survey
- C. Scan the baby and arrange fetal monitoring
- D. Transfer to theatre for immediate delivery of baby
- E. X-ray cervical spine



- 34.** A 55 year old man is brought to the emergency department with 2 hours of severe left sided chest pain.

A pre-hospital ECG shows left bundle branch block, for which paramedics gave aspirin and glyceryl trinitrate spray.

He is sweating and distressed. His pulse is 85 bpm, BP 99/54 mmHg, respiratory rate 22 breaths per minute and oxygen saturation 96% breathing air. His GCS score is 15/15.

What is the most appropriate management?

- A.** Continue breathing air
- B.** Start 28% oxygen via a Venturi mask
- C.** Start 40% oxygen via a Venturi mask
- D.** Start oxygen 2 L/min via nasal cannulae
- E.** Start oxygen 15 L/min via a non-rebreathe mask

- 35.** A 25 year old man has taken an overdose of 16 paracetamol tablets. He became very sad earlier that day after an argument with a friend. His mood changes between being happy and sad several times per week. He struggles with concentration and gets angry easily. He has frequently been excessively drunk on nights out. He has never experienced psychotic symptoms.

What is the most likely diagnosis?

- A.** Adjustment disorder
- B.** Bipolar disorder
- C.** Borderline personality disorder
- D.** Dissocial personality disorder
- E.** Unipolar depressive episode



- 36.** A 52 year old woman has a brief episode of dizziness on standing. She has had 4 days of dysuria, loin pain and fever. She has been feeling tired for 4 months and has lost 3 kg in weight.

Her temperature is 37.4°C, pulse 90 bpm, BP 100/55 mmHg lying and 90/50 mmHg sitting, respiratory rate 18 breaths per minute and oxygen saturation 95% breathing air. Her JVP is not visible.

Investigations:

Haemoglobin	106 g/L	(115–150)
White cell count	$14 \times 10^9/\text{L}$	(3.8–10.0)
Platelets	$201 \times 10^9/\text{L}$	(150–400)

Sodium	130 mmol/L	(135–146)
Potassium	5.6 mmol/L	(3.5–5.3)
Urea	9.5 mmol/L	(2.5–7.8)
Creatinine	98 $\mu\text{mol/L}$	(60–120)

Random plasma glucose 3.2 mmol/L

12-lead ECG: sinus rhythm

What is the most appropriate additional investigation?

- A. CT of head
- B. CT pulmonary angiography
- C. Echocardiography
- D. Plasma cortisol and adrenocorticotrophic hormone
- E. Urinary and serum osmolality

- 37.** A 39 year old woman with metastatic lung cancer has 24 hours of back pain at the L1 level. She has also developed leg weakness and urinary retention.

What is the most appropriate investigation?

- A. CT of spine
- B. Isotope bone scan
- C. MR imaging of spine
- D. PET–CT
- E. X-ray of thoracic and lumbar spine



- 38.** A 75 year old woman has breathlessness on exertion and a cough productive of white sputum throughout the day. She has never had haemoptysis. She has lost 2kg in weight . She has had two chest infections in the past year treated with a short course of steroids and antibiotics. She has a 15 pack-year smoking history.

Her heart rate is 82bpm.

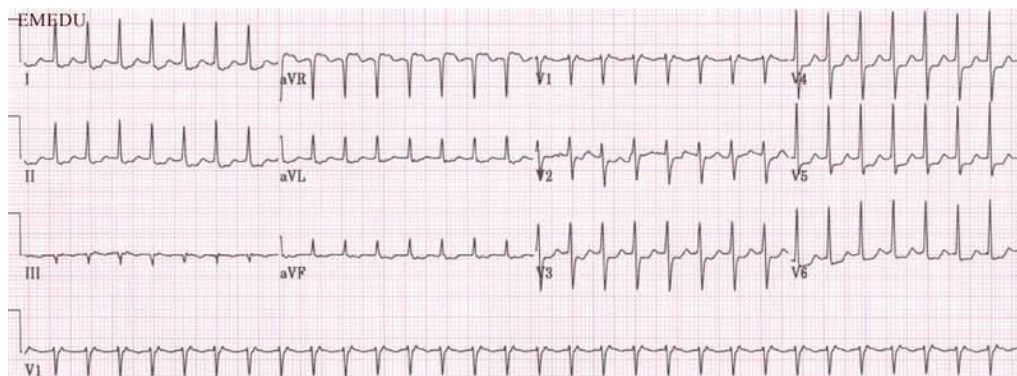
Investigations:  
Chest X-ray is normal.

What is the most appropriate diagnostic investigation?

- A.** Cardiopulmonary exercise test
- B.** Echocardiography
- C.** High resolution CT scan of thorax
- D.** Spirometry
- E.** Sputum cytology

- 39.** A 32 year old man has 60 minutes of palpitations that started during a night out dancing with friends. This is associated with chest pain and shortness of breath.

Investigations:  
ECG (see image)



Which diagnosis is shown on the ECG?

- A.** Atrial fibrillation
- B.** First degree heart block
- C.** Sinus tachycardia
- D.** Supraventricular tachycardia
- E.** Ventricular tachycardia



- 40.** A 82 year old woman is oliguric 8 hours after an emergency sigmoid colectomy for a perforated diverticulum. She has chronic kidney disease stage 3, peripheral vascular disease and type 2 diabetes mellitus. She takes metformin and ramipril.

Her pulse is 110 bpm, BP 94/60 mmHg and JVP not visible. Her urine output has been 10 mL per hour for the past 4 hours.

She has been given 2 L of Hartmann's solution since returning from theatre.

Investigations:

Urea 14.9 mmol/L (2.5–7.8)

Creatinine 188  $\mu$ mol/L (60–120)

What is the most likely cause of her oliguria?

- A.** Acute tubular necrosis
- B.** Catheter obstruction
- C.** Intraoperative ureteric injury
- D.** Prerenal hypovolaemia
- E.** Renal artery occlusion

- 41.** A 39 year old man is brought to the emergency department having hit his head on a tree trunk when he lost control of his bicycle.

He has a minor scalp abrasion. His GCS is 15/15 and there are no focal neurological signs.

Seven hours later he collapses, at which point his GCS is 6/15. A CT scan of brain reveals a lens-shaped haemorrhage in the right parietal region.

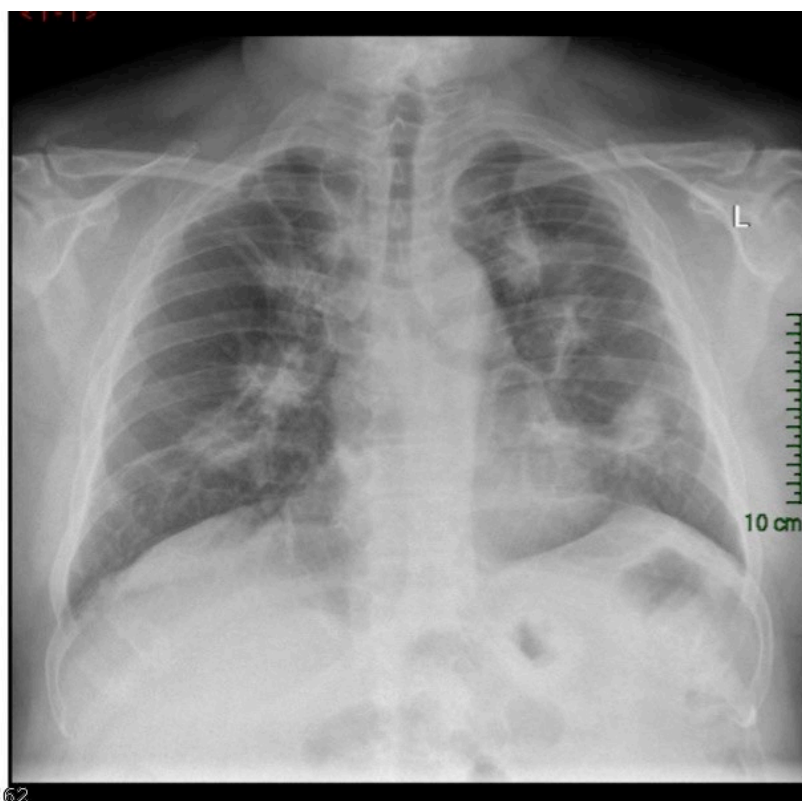
What is the most likely vessel to be injured?

- A.** Anterior communicating artery
- B.** Basilar artery
- C.** Bridging veins
- D.** Middle meningeal artery
- E.** Vertebral artery

- 42.** A 68 year old woman has worsening chest discomfort over 11 days. She has a dry cough and has lost 3 kg in weight over the last 2 months. She is a non-smoker. She retired as a builder 15 years ago.

She has a temperature of 37.1°C. Both lung fields sound clear.

Her chest X-ray is shown (see image).



What is the most likely underlying diagnosis?

- A.** Mesothelioma
- B.** Metastatic cancer
- C.** Pulmonary fibrosis
- D.** Pulmonary tuberculosis
- E.** Sarcoidosis





- 43.** Researchers compare the diagnostic accuracy of a new serological test for SARS-Cov-2 against the nose and throat swab currently being used for clinical diagnosis in the UK. The new test detects all 23 confirmed cases of the disease that were positive by the current test. 92% (230/250) of patients who tested negative with the current test are also negative by the new rapid diagnostic test.

Which statement is correct?

- A.** The false negative rate of the new test is 0%
- B.** The false positive rate of the new test is 92%
- C.** The sensitivity of the new test is 92%
- D.** The specificity of the new test is 8%
- E.** The specificity of the new test is 100%

- 44.** A 24 year old man has 12 hours of a severe headache of sudden onset. When the headache started, he lost consciousness briefly and vomited; he also reports photophobia. He has severe hypertension.

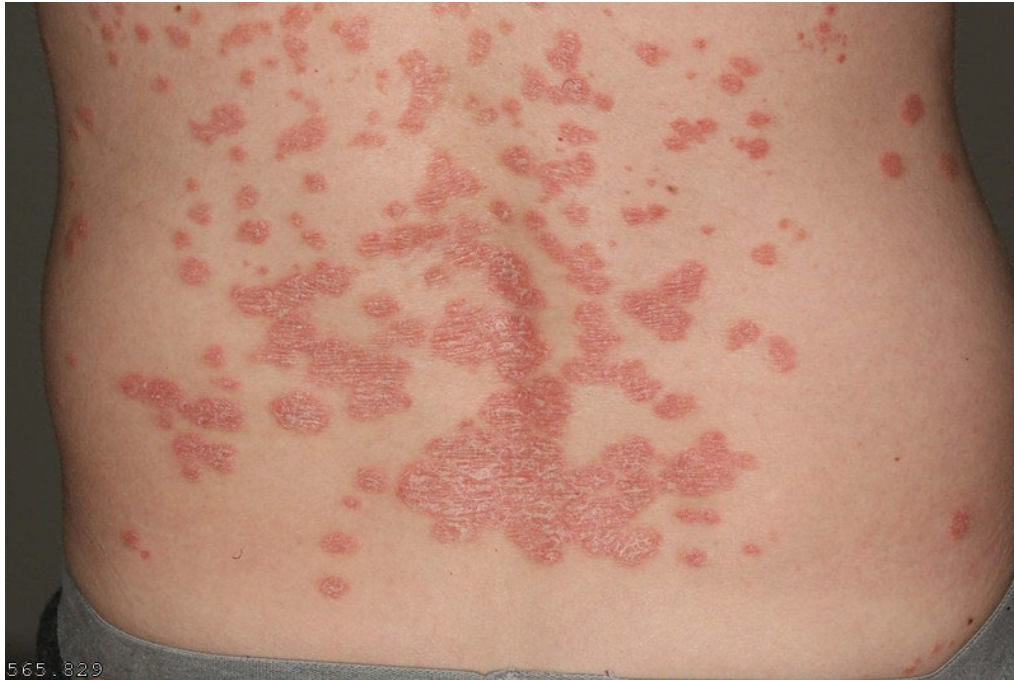Neurological examination is normal. A non-contrast CT scan of brain is normal.

What is the most appropriate next step in management?

- A.** Carotid Doppler studies
- B.** Lumbar puncture
- C.** MR scan of brain
- D.** MR imaging of brain with MR venography
- E.** No future investigations required

- 45.** A 33 year old man has 6 months of an itchy, well demarcated rash that has partially responded to topical moisturiser.

There are lesions symmetrically distributed over the extensor surface of his elbows, scalp and back, which are 2–10 cm in diameter (see image).



What is the most likely diagnosis?

- A.** Atopic dermatitis
- B.** Pityriasis versicolor
- C.** Plaque psoriasis
- D.** Seborrhoeic dermatitis
- E.** Tinea corporis infection



- 46.** A 21 year old woman has recurrent pulsating frontal headaches lasting up to 2 days, associated with nausea. The headache is usually preceded by numbness that starts in the hand, travels up the arm and then involves the face, lips and tongue. These headaches cause her to take time off work up to four times each month.

What is the most appropriate treatment to reduce the frequency of these episodes?

- A.** Acupuncture
- B.** Gabapentin
- C.** Propranolol
- D.** Sumatriptan
- E.** Venlafaxine

- 47.** A 60 year old man has increasing fatigue. He has noticed intermittent difficulty swallowing, usually in the evening. He has hypothyroidism and takes levothyroxine. He smokes.

There is bilateral mild ptosis. Neurological examination is otherwise normal.

What is the most likely diagnosis?

- A.** Guillain–Barré syndrome
- B.** Migraine
- C.** Multiple sclerosis
- D.** Myasthenia gravis
- E.** Stroke



- 48.** Six students living in the same hall of residence have developed diarrhoea and vomiting within 48 hours of each other. There is no blood in the stool, they have not eaten similar foods and have no history of foreign travel.

A doctor requests stool samples from each to confirm the likely diagnosis.

What test is most likely to confirm the diagnosis?

- A.** Clostridium difficile enzyme assay and toxin detection
- B.** Faecal elastase test
- C.** Stool for culture and sensitivity
- D.** Stool for viral PCR
- E.** Stool microscopy for ova, cysts and parasites

- 49.** A 58 year old woman has 6 months of worsening right-sided hip pain caused by osteoarthritis. Her pain is partially controlled by regular ibuprofen gel. She remains active. She has peptic ulcer disease and heart failure. She takes bisoprolol fumarate, aspirin and simvastatin.

She has crepitus on active and passive movements of both hips. Her BMI is 30 kg/m<sup>2</sup>.

What is the most appropriate management?

- A.** Add paracetamol as required
- B.** Add regular celecoxib
- C.** Add regular oral ibuprofen and lansoprazole
- D.** Refer for acupuncture
- E.** Refer for hip replacement surgery